

The challenge of diagnosing and classifying eosinophilia and eosinophil disorders: A review

AGNIESZKA SZYMCZYK¹, JAKUB JAWORSKI², MONIKA PODHORECKA³

¹Department of Hematology, National Medical Institute of the Ministry of Interior and Administration, Warsaw, Poland

²Doctoral School, Medical University of Lublin, Poland

³Chair and Department of Haematology and Bone Marrow Transplantation, Medical University of Lublin, Poland

Abstract

Eosinophilia is a feature of multiple conditions, both hematologic and non-hematologic, and may be associated with organ damage. The pathogenesis of eosinophilia can follow two distinct pathways. Primary eosinophilia is caused by a cell-intrinsic mechanism originating from clonal expansion of eosinophils through acquisition of a somatic mutation, such as FIP1L1-PDGFR. In recent years, great progress has been made in the field of pathogenesis and molecularly targeted therapy of neoplastic eosinophilia. The diagnostic procedure should include, among other things, morphologic analysis of blood and bone marrow samples, cytogenetics and fluorescence in situ-hybridization tests to detect evidence of an acute or chronic myeloid or lymphoid disorder. Secondary eosinophilia follows a cell-extrinsic mechanism as a response to exogenous cytokines. In most clinical cases, peripheral blood eosinophilia is reactive and typically associated with non-hematological disorders such as infections, allergic conditions, connective tissue disorders, vasculitis, malignancy, or endocrinopathies. Nonetheless, the cause of most cases of hypereosinophilic syndrome remains unknown. In this article, we present a short review focused on differential diagnosis of eosinophilia and eosinophilic disorders. The diagnosis of eosinophilia is a challenge for physicians; thus this review may be useful in clinical practice.

Key words: eosinophilia, FIP1L1-PDGFR, hypereosinophilic syndrome, chronic eosinophilic leukemia.

(*Cent Eur J Immunol* 2024; 49 (1): 60-69)

Introduction

Eosinophils are highly specialized myelopoietic effector cells circulating in peripheral blood that are able to produce and store a number of biologically active molecules. These include major basic protein (PRG2), eosinophil cationic protein (ECP), eosinophil neurotoxin, thromboxane A2 (TXA2), prostaglandins, leukotrienes, and cytokines, such as tumor necrosis factor α (TNF- α) [1-3]. Activated eosinophils release these mediators, thereby influencing homeostasis and tissue integrity [2]. In the case of proliferation and permanent activation, eosinophils can induce inflammatory processes and changes in the microenvironment. This can result in fibrosis or thrombosis with a potential for end-organ damage [2, 3]. In healthy individuals, eosinophils account for about 3% to 5% of leukocytes circulating in peripheral blood. The upper limit of absolute eosinophil count (AEC) in normal peripheral blood is $0.35 \times 10^9/l$ to $0.5 \times 10^9/l$ [4, 5]. AEC above this range is considered pathological. The degree of increased eosinophils level is arbi-

trarily assigned as: mild (higher than upper normal range to $1.5 \times 10^9/l$), moderate ($1.5 \times 10^9/l - 5 \times 10^9/l$), or severe ($> 5 \times 10^9/l$) [4-7]. Marked and persistent eosinophilia (AEC $> 1.5 \times 10^9/l$) is referred to as hypereosinophilia (HE) [3, 8]. When irreversible organ damage is involved in HE, the term hypereosinophilic syndrome (HES) is applied [4, 5, 8].

Eosinophilias encompass a broad range of non-hematologic (secondary or reactive) and hematologic (primary, clonal) disorders that may be associated with tissue damage [5, 9]. The pathogenesis of eosinophilia can follow two distinct pathways. Primary eosinophilia is caused by a cell-intrinsic mechanism originating from clonal expansion of eosinophils through acquisition of a somatic mutation, such as that of FIP1L1-PDGFR. Secondary eosinophilia follows a cell-extrinsic mechanism as a response to exogenous cytokines [6]. In most clinical cases, peripheral blood eosinophilia is secondary (reactive) and is associated with non-hematological disorders such as infections, allergic conditions, connective tissue disorders, vasculitis,

Correspondence: Agnieszka Szymczyk, MD, MSc, PhD, Department of Hematology, National Medical Institute of the Ministry of Interior and Administration, Warsaw, Poland, 137 Wołoska St., 02-507 Warsaw, Poland, phone: +48 47 722 2104, e-mail: agnieszka.szymczyk.med@wp.pl
Submitted: 19.05.2019, Accepted: 17.01.2024

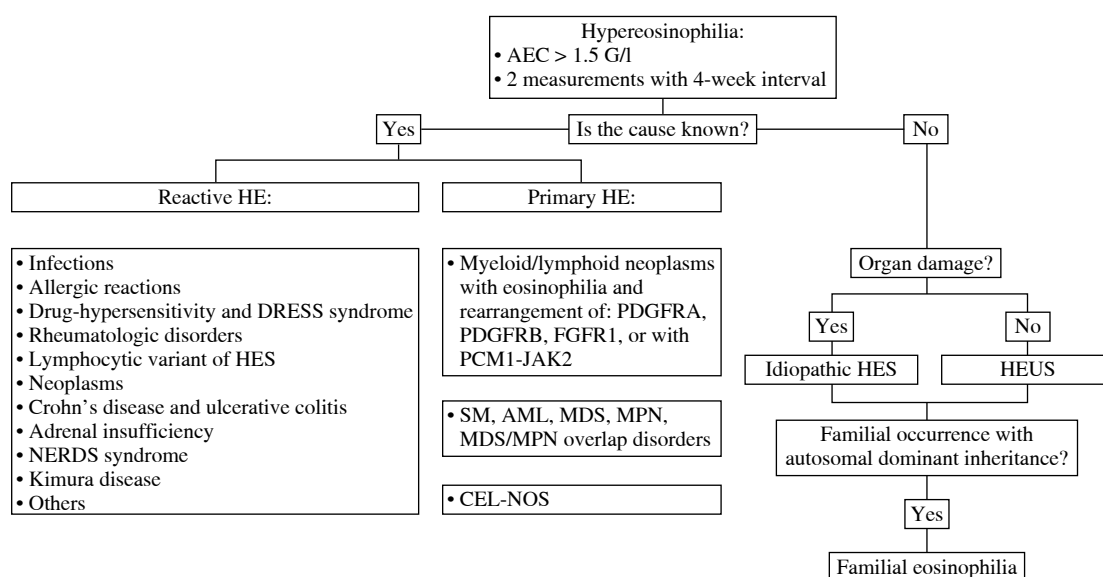


Fig. 1. Differential diagnosis and classification of hypereosinophilia

malignancy, or endocrinopathies [5, 9, 10]. Because differential diagnosis of eosinophilia is rather complicated, the exclusion of secondary causes should be the first approach. Primary eosinophilia requires not only a thorough medical history and physical examination, but also precise and sophisticated laboratory analyses [11, 12]. Diagnostic tests should include morphologic analysis of the blood and bone marrow samples, cytogenetics and fluorescent *in situ*-hybridization analyses to detect evidence for an acute or chronic myeloid or lymphoid disorder [5]. The scheme of diagnosis and classification of HE is shown in Figure 1.

The aim of this article is provide an overview of possible causes of eosinophilic disorders based on medical literature. It may support everyday clinical practice, being useful in the differential diagnosis of eosinophilia.

Eosinophils – development and functions

Eosinophils were described and characterized by Paul Ehrlich in 1879 [12]. The human hematopoietic stem cell (hHSC) differentiates into the human common myeloid progenitor (hCMP), on which the interleukin (IL)-5 receptor α chain is not expressed (IL-5R α^-). The hCMP is capable of producing human granulocyte/macrophage progenitors (hGMP), human megakaryocyte/erythrocyte progenitors (hMEP) and human eosinophil lineage-committed progenitors (hEoP). The hEoP cell has a specific phenotype: “IL-5R α^+ (CD125) CD34 $^+$ CD38 $^+$ IL-3R α^+ CD45RA $^-$ ” and differs only in the eosinophil line. Probably, part of the hEoP population also derives from the human multipotent progenitor cells (hMPP) and HSC.

The process of hCMP differentiation into mature and functional eosinophils is very complex and is based on the interaction of many transcription factors [13, 14]. However, a detailed understanding of eosinophil differentiation and development is the basis for the introduction of targeted therapy in eosinophilic diseases

The best-known eosinopoietic cytokine is IL-5. Its role is important, but its presence is not necessary for the production of eosinophils. Mepolizumab (anti-IL-5 antibody) reduces the amount of mature forms, but not hEoPs [14, 15]. Other cytokines, IL-33, IL-3 and GM-CSF, are involved in eosinophil physiology as well [13, 16]. Eosinophils reside in the hematopoietic and lymphatic organs such as the bone marrow, spleen, lymph nodes, and thymus. In addition, eosinophils physiologically migrate to digestive tract organs, the female reproductive tract, and the mammary gland [17]. They secrete a large number of various cytokines. For instance, IL-4 is involved in immunoglobulin E (IgE) production and the migration of immune cells to the place affected by the inflammatory process in which IL-13 is also involved. Furthermore, IL-13 mediates asthma exacerbations by stimulating mucus production [13, 18]. The capacity of eosinophils for extracellular trap cell death (EETosis) seems to play a significant role in the pathogenesis of eosinophilic disorders. Eosinophils use their own mitochondrial or nuclear DNA in this process [13, 19].

In the course of eosinophilia various organ damage may occur due to cytotoxic activity of eosinophils and secondary fibrosis of affected tissues. In a quarter of patients, thromboembolic complications and organ ischemia are observed [20]. Various forms of skin lesions are the most

common manifestation. Cardiovascular diseases, central and peripheral nervous system disorders, pulmonary disruption, gastrointestinal manifestations and others are also possible [20-22].

Up-to-date classification of hyper-eosinophilia and hypereosinophilic syndromes

Hyper-eosinophilia is a heterogeneous group of hematological disorders characterized by marked and persistent eosinophilia in the peripheral blood and tissues [23]. The concept of HES was first proposed by William R. Hardy and Robert E. Anderson in 1968 in an article that reported three cases. The described patients had eosinophilia and organ damage and the diagnosis of eosinophilic leukemia was doubtful [24]. The modern definition of HES is based on the historical criteria outlined by Chusid *et al.* in 1975: the AEC is $> 1.5 \times 10^9/l$ for more than 6 months, and tissue damage is present. In addition, the underlying cause should be unknown [25].

However, due to new discoveries of pathogenesis, molecular mechanisms and the course of HE a subsequent revision was necessary [20, 24]. The classification developed by the International Cooperative Working Group on Eosinophil Disorders (ICOG-EO) in 2011 is currently in force (Figs. 2 and 3) [8]. The ICOG-EO unified the prior classification criteria and adapted them to the latest molecular biology discoveries. The concept of HE was defined as: AEC $> 1.5 \times 10^9/l$, confirmed twice with at least a four-week interval. The reason for shortening the time criterion is to avoid complications that may develop over a six-month period. In addition, the concept of tissue HE was determined. This is manifested as bone marrow HE

(eosinophils represent $> 20\%$ of nucleated cells) or intense tissue infiltration by eosinophils, subjectively evaluated by the pathomorphologist (presence of granule proteins even without massive infiltration of live cells is sufficient). To diagnose HES, it is necessary to show HE in the peripheral blood, regardless of its origin (clonal, reactive or idiopathic) and to identify organ damage or functional disorders that have a direct relationship with HE. At least one clinical manifestation resulting from tissue HE should be proven. Severe eosinophilia can result in thrombosis, neuropathy, cutaneous and mucosal lesions and organ disorders (e.g. liver, kidneys or pancreas involvement). The eosinophil infiltrations or aggregates of granule proteins indicate the association of peripheral blood eosinophilia with the observed pathology. It is necessary to exclude other possible causes of these disorders. Importantly, according to the ICOG-EO, the diagnosis of HES cannot be made when the only clinical manifestation is eosinophilic gastroenteritis, eosinophilic pneumonia, or other examples of single-organ disease listed in the classification (Table 1). In these entities, the role of eosinophils has not been fully elucidated [8, 20]. Initial single-organ manifestation, on the other hand, does not exclude HES. Therefore, definite exclusion of these locations from the HES spectrum seems controversial and unclear. According to Kahn *et al.*, most cases of HE with single-organ involvement should be treated as HES, regardless of the number of organ manifestations and their location [24]. When the disease is life-threatening, the time criterion is unnecessary to recognize HES [8, 20].

Clonal eosinophil proliferation leads to primary HES. Secondary causes of HE result in a non-clonal population. A diagnosis of idiopathic HES (HES-I) requires exclusion of all primary and secondary causes of hypereosinophilia and lymphocyte-variant hypereosinophilia [9, 20].

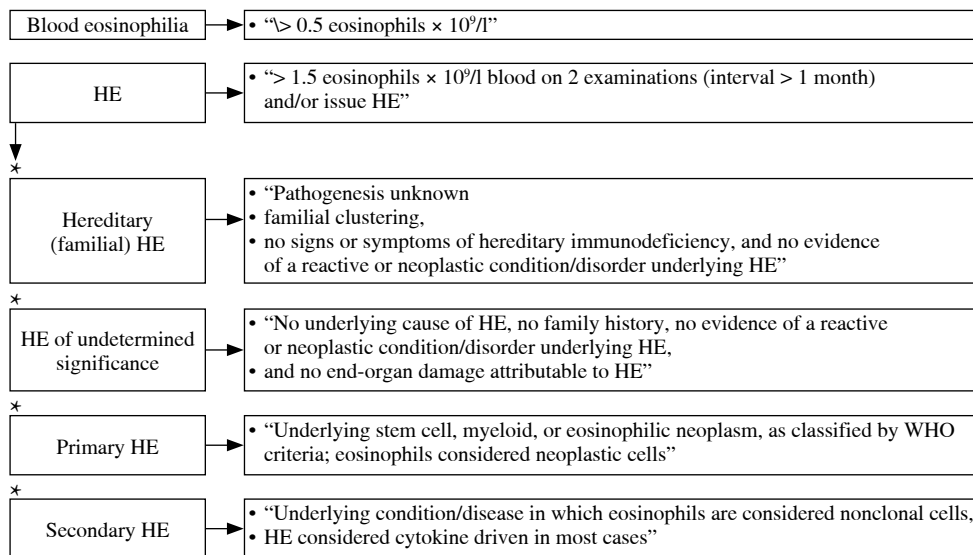


Fig. 2. Classification of hypereosinophilia (HE) – ICOG-EO 2011

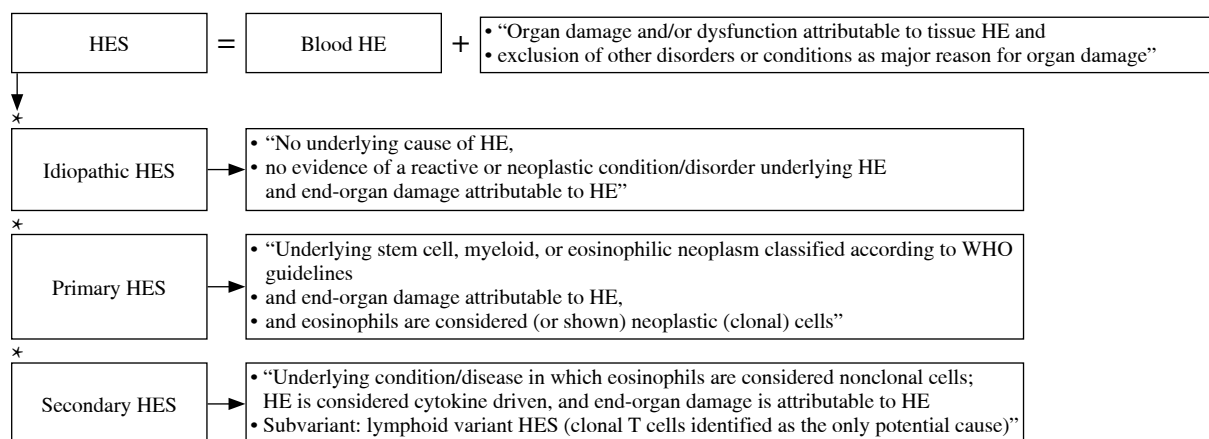


Fig. 3. Classification of hyper-eosinophilic syndromes (HES) – ICOG-EO 2011

Table 1. Organ-restricted conditions in which the effect of eosinophilia remains unclear. Modified table taken from P. Valent *et al.*, 2012 (ICOG-EO 2011)

In these conditions the role of eosinophils has not been fully elucidated. The diagnosis of hyper-eosinophilic syndrome cannot be made when one of these entities is the only clinical manifestation of hyper-eosinophilia.	
Single-organ pathologies (nondermatologic)	Dermatologic diseases
Eosinophilic gastrointestinal disorders (eosinophilic esophagitis, gastroenteritis, or colitis)	Allergic contact dermatitis
Eosinophilic pancreatitis	Angiolymploid hyperplasia with eosinophilia
Eosinophilic hepatitis	Annular erythema of infancy
Eosinophilic ascites	Atopic dermatitis
Pulmonary eosinophilic syndromes (eosinophilic asthma, bronchitis, pneumonia, or pleuritis)	Bullous pemphigoid
Eosinophilic nephritis	Coccidioidomycosis
Eosinophilic cystitis	Drug eruptions
Eosinophilic endometritis and myometritis	Eosinophilic fasciitis
Eosinophilic mastitis	Eosinophilic, polymorphic, and pruritic eruption associated with radiotherapy
Eosinophilic ocular disorders	Eosinophilic pustular folliculitis: all variants
Eosinophilic myocarditis	Erythema toxicum neonatorum
Eosinophilic panniculitis	Eosinophilic ulcer of the oral mucosa
Eosinophilic synovitis	Eosinophilic vasculitis
Eosinophilic fasciitis	Granuloma faciale
	Infestations (parasites/ectoparasites, including scabies, bed bugs, and cutaneous larva migrans)
	Incontinentia pigmenti
	Kimura disease
	Langerhans cell histiocytosis
	Mycosis fungoides and Sezary syndrome
	Pachydermatous eosinophilic dermatitis
	Pemphigoid variants, including bullous pemphigoid and pemphigoid gestationis
	Pemphigus variants
	Pregnancy-related dermatoses
	Pseudolymphoma
	Urticaria/angioedema
	Vasculitis
	Wells syndrome (eosinophilic cellulitis)

The new concept of hypereosinophilia of undetermined significance (HEUS) has been introduced. Diagnosis of HEUS can be made when no obvious reason is found and no organ damage (necessary to diagnose HES-I) occurs with HE [8, 9]. A hereditary form of eosinophilia is also known. So-called familial eosinophilia (FE) occurs in subsequent generations with autosomal dominant inheritance, probably associated with the 5th chromosome (locus 5q31-q33). In this locus there are IL-3, IL-5 and GM-CSF genes; however, the causative abnormality does not concern them. Organ damage is present only in some cases [20, 26].

Causes of secondary hypereosinophilia

Secondary eosinophilia is defined as all disease entities that cause non-clonal proliferation of eosinophils stimulated by cytokines.

Infections

Numerous parasitic, bacterial and fungal diseases cause an increase in the AEC. Parasitosis should be suspected in the case of immigrants or other people returning from endemic areas. The diagnostic process may be very laborious due to the enormous number of possible disease entities, low sensitivity of stool examination and limited availability of serological and molecular tests. Thus, detailed anamnesis plays an essential role in making a successful clinical diagnosis. However, it should be remembered that a subclinical or atypical course is very common [27, 28]. Enumerating and describing all parasitoses causing eosinophilia goes beyond the scope of this article. Trichinellosis, fascioliasis, schistosomiasis and echinococcosis are the most prevalent disease entities reported in Europe and North America manifested by acute eosinophilia. The etiology of chronic eosinophilia may be associated for instance with strongyloidiasis, clonorchiasis, opisthorchiasis and paragonimiasis [28].

Trichinella spiralis infestations have a global reach. The risk factor is pork, venison or bear consumption [28]. Thermal treatment of food eliminates larvae and prevents infection [29]. The AEC usually exceeds $1 \times 10^9/l$. Symptoms, i.e. fever, myalgia and facial swelling, develop after around 1-4 weeks of exposure (from a few days to even 1-2 months) [28, 30, 31]. The mature forms of *Fasciola hepatica* live in the bile ducts and are manifested by elevated transaminase and bilirubin levels. Infestation occurs through the consumption of feces-contaminated water [28, 32]. Fever, HE and abdominal pain are the main acute phase symptoms. *Fasciola* is a cosmopolitan parasite; it is noted that 2.6 million humans are infected [28, 32]. Acute schistosomiasis, called Katayama fever, is the result of skin penetration by cercariae (residing in contaminated water) and subsequent migration of schistosomulae. HE (even $7 \times 10^9/l$) may be accompanied by flu-like symp-

toms, cough and diarrhea [28, 33]. Chronic schistosomiasis usually occurs with mild eosinophilia, which is present in half of the cases. Depending on the fluke species it can cause hepatosplenic manifestation, with fibrosis and portal hypertension, the pulmonary form, with angiopathy and secondary right heart failure, as well as genitourinary symptoms. Anyone returning from Africa with fever and eosinophilia should be screened for schistosomiasis [28]. *Echinococcosis*, the presence of cysts in various organs, is rarely a cause of eosinophilia. It occurs following hydatid cyst rupture, especially spontaneous leakage of contents into the lungs or bile ducts. An atypical clinical picture is a source of frequent misdiagnosis. Rapid iatrogenic perforation of the cyst wall initially causes neutrophilia and the AEC is initially within the normal range. Eosinophilia gradually rises over the next few days. A cyst rupture is a very serious condition that can cause anaphylaxis [28, 34-36]. *Strongyloides stercoralis* is the most frequent etiologic factor causing chronic eosinophilia. It is usually mild [42]. The disease can be asymptomatic or cause gastrointestinal and cutaneous symptoms (larva currens). Other organ manifestations are also observed due to larval wandering [28]. *Ascaris lumbricoides* infestation is rarely symptomatic. In chronic ascariasis eosinophilia is infrequent. An acute infection can occur as an eosinophilic pneumonia (Loeffler's syndrome) caused by larval migration [28, 38]. Other helminths (e.g. *Ancylostoma duodenale* and *Strongyloides stercoralis*) can also lead to Loeffler's syndrome. Nevertheless, there are other causes of eosinophilic pneumonia-neoplasms, drugs and inflammatory diseases. Parasitosis is an important entity in differential diagnosis of asthmatic symptoms with peripheral eosinophilia, notably in endemic areas. In the case of an infectious etiology, steroid therapy impairs the immune system and leads to escalation of symptoms [38]. In conclusion, increase in the AEC requires parasitological diagnosis. Nonetheless, absence of significant eosinophilia does not exclude parasitic disease [28, 38].

The possibility of fungal infection should also be considered. Importantly, different location of lesions is possible, for instance, the digestive tract (e.g. basidiobolomycosis) and respiratory system (e.g. bronchopulmonary aspergillosis or coccidioidomycosis) [28].

Bacterial infections can also occur with HE [39]. The causative relationship seems to be confirmed by the AEC reduction after treatment of Lyme disease. To date, only one case of cerebrospinal fluid eosinophilia has been described [40]. Other reports indicate the possibility of transient synovial fluid eosinophilia in borreliosis-associated arthritis and diffuse fasciitis with eosinophilia [41]. Similarly, the relationship between tuberculosis and peripheral HE is not completely resolved. However, a decrease in the AEC after anti-tubercular treatment was observed [42].

Although eosinophilia is frequently observed in HIV-infected patients, it is usually related to secondary

diseases due to immunodeficiency. Insightful diagnostics is important because of the tendency to aggressive infections and cancer development [28, 43].

Allergic diseases

The exclusion of allergic diseases is an extremely important element of differential diagnosis of eosinophilia. Asthma is defined as airway hyperresponsiveness characterized by inflammation and chronic course. Bronchial hyperresponsiveness causes reversible obstruction, with the possibility of becoming persistent [18]. Inflammation occurs with the predominance of neutrophils or eosinophils; the latter better responds to steroid therapy. Atopic asthma is known to have an allergic etiology and specific IgEs are detected in plasma. Furthermore, the response to inhaled steroids is better than in non-atopic cases. Sputum eosinophilia is strongly associated with allergic-type and correlates with the asthma severity [18, 44]. Excluding exacerbations, the AEC is within the normal range or slightly elevated. Moreover, non-allergic asthma with adult onset can be manifested by a HE [18, 45]. Allergic fungal airway disease is another lung disorder accompanied by eosinophilia [18]. *Aspergillus fumigatus*, *Candida albicans* and *Penicillium* species are the main etiological factors. Sensitization coexists with asthma, chronic obstructive pulmonary disease and cystic fibrosis [46]. Allergic eosinophilic esophagitis (AEE), atopic dermatitis (AD) and others can also lead to an increase in the amount of eosinophils. Moreover, AEE and AD are interrelated. Some patients with AEE have AD features [47, 48].

Drug-induced hypereosinophilia

Medication history is crucial in the differential diagnosis of HE. The hypersensitivity reaction is common especially after antibiotics. Medicines can also cause acute eosinophilic pneumonia [27]. A notable but rare condition is DRESS (drug reaction with eosinophilia and systemic symptoms) syndrome. It is manifested by skin lesions and possible life-threatening systemic symptoms [49]. DRESS syndrome was first described in 1930 [49] but the current terminology and first classification criteria of this condition were established in 1996 [50]. Skin lesions are the most characteristic manifestations. However, they are very heterogeneous, from morbilliform maculopapular rash to blisters and erythroderma. The lesions are usually located on the skin above the diaphragm, sometimes also on mucous membranes. Systemic symptoms include fever, lymphadenopathy, hepatic failure, thyroiditis, myositis, myocarditis, pericarditis, uveitis, polyneuropathy, encephalitis and meningitis [49]. Eosinophils and atypical lymphocytes are visible in peripheral blood film. The most common causes of the DRESS syndrome are taking antiepileptic drugs, sulfonamides and antivirals. Other described medicines include allopurinol, pro-

ton pump inhibitors, strontium ranelate and minocycline [49, 51]. The pathogenesis of the disease has not been fully elucidated. However, there are four potential causative mechanisms. First, the pharmacogenetic theory is based on human leukocyte antigens (HLA) polymorphism. Certain HLA mutations are potential risk factors for drug-induced cutaneous adverse reactions [49]. The second mechanism is based on the hypersensitivity reaction (type IVb). Drugs as very small particles have the properties of haptens or prohaptenes. Eosinophils, basophils and mast cells are activated by IL-4, IL-5 and IL-13 (Th2 – cytokines). Similar to the previous, p-i (pharmacologic interaction with immune receptors) concept which assumes that the drug molecules activate effector cells by forming direct noncovalent bonds with T cell receptor (TCR) or HLA [49, 52]. The last proposed theory is an infectious etiology. DRESS syndrome may be associated with herpesvirus reactivation (i.e. Epstein-Barr virus [EBV], cytomegalovirus [CMV], human herpesvirus [HHV]-6, HHV-7). This relationship is noticeable in 60% of cases. Nonetheless, recent analyses indicate that this causation may also be secondary to immune stimulation by the drug [49, 53]. The first symptoms occur after 2 weeks or even 2 months after the exposure [51]. This may confirm the theory of delayed hypersensitivity, in which T lymphocytes need 4-21 days for activation and expansion [49].

Rheumatologic disorders

Rheumatic diseases particularly associated with eosinophilia include: eosinophilic granulomatosis with polyangiitis (EGPA), immunoglobulin G4-related disease (IgG4RD), diffuse fasciitis with eosinophilia (DFE), eosinophilia-myalgia syndrome (EMS) and eosinophilic myositis (EM). Furthermore, eosinophilia is observed in numerous other conditions, i.e. rheumatoid arthritis, systemic lupus erythematosus, Sjögren syndrome, systemic sclerosis, Behçet's disease, polymyositis, dermatomyositis, inclusion body myositis, and granulomatosis with polyangiitis [54].

EGPA (formerly Churg-Strauss syndrome) is characterized by allergic manifestations, asthmatic symptoms, vasculitis (inflammation of small and medium vessels), and peripheral and tissue eosinophilia with the formation of granulomas. Vasculitis is manifested by the involvement of the skin, kidneys, heart, peripheral nerves and other organs. The significant increase in the AEC seems to be strongly involved in the pathogenesis of EGPA. Furthermore, an increase in IL-5 level is also observed and the efficacy of mepolizumab seems to confirm this theory [54, 55]. Antineutrophil cytoplasmic antibody (ANCA) is not symptomatic for EGPA due to the presence in other disease entities. Patients with EGPA are mostly ANCA-negative [54, 56]. Differentiation with HES is an important part of diagnostics. Both entities are very similar, especially when there is no ANCA [57]. The prognosis is quite good. The five-year survival rate is 92% [54].

IgG4RD is a broad spectrum of autoimmune disorders characterized by infiltration of IgG4 (+) plasma cells and fibrosis of affected tissues. Tissue or peripheral eosinophilia may also be present. Interestingly, an increased serum level of IgG4 does not occur in all cases and is not required for diagnosis [58].

DFE is manifested by deep induration of subcutaneous tissue and fissures, especially on the limbs. Differentiation with scleroderma is necessary, although the features of both diseases can overlap. Some cases of morphoea profunda may be incorrectly described as DFE. Peau d'orange appearance (orange peel skin) and the groove sign are characteristic symptoms of DFE. The skin induration is preceded by swelling and erythema. The previous nomenclature – eosinophilic fasciitis – is incorrect because tissue infiltration of eosinophils is not required for the diagnosis [54].

Another medical entity with a similar clinical course is EMS. Peripheral eosinophilia and myalgia are the main manifestation of the disease. EMS may also be accompanied by edema, skin lesions, arthralgia, neuropathy, dyspnoea and fever. The most possible trigger factor is L-tryptophan. At the end of the 20th century, there was an epidemic of EMS in the United States. The FDA intervened and withdrew products containing L-tryptophan from sale [54, 59].

Modest data on EM are collected; thus, epidemiology, risk factors and pathogenesis are unknown. EM includes three entities: focal eosinophilic myositis, eosinophilic polymyositis and eosinophilic perimyositis. Eosinophils are probably directly involved in muscle damage and peripheral eosinophilia is one of the proposed diagnostic criteria [54, 60].

Lymphocytic variant of hypereosinophilia

Lymphocyte-variant hypereosinophilia is connected with expansion of the population of T-cells with abnormal immunophenotype (CD3⁺CD4⁻CD8⁻ or CD3⁻CD4⁺) that produce cytokines, such as IL-5 and in some cases IL-4 and IL-13 [9, 61]. The primary disease manifestations observed in most patients are cutaneous signs and symptoms. The condition is both a clonal process in regards to the abnormal T-cell population and a reactive process because eosinophilia occurs as a reaction to growth factors released by T-cells [9].

Other secondary causes of eosinophilia

Secondary eosinophilia may be the result of hematological or non-hematologic malignancies. Interestingly, the role of eosinophil infiltration in the tumor environment is ambiguous. Tissue eosinophilia is able to promote tumor growth by angiogenesis-stimulating properties. Nonetheless, eosinophils have cytotoxic activity against tumor cells. Moreover, activated eosinophils accompanied by cancer-specific CD8⁺ T cells support the anti-tumor ac-

tivity of the immune system. The participation of eosinophils in T-cell chemotaxis, macrophage polarization and even inhibition of neovascularization has been described. Peripheral eosinophilia has been found to correlate with the metastatic process in some studies [62, 63].

Furthermore, inflammatory bowel diseases (e.g. Crohn's disease or ulcerative colitis) coexisting with eosinophilia have a more aggressive course. This is evident in the frequency of hospitalizations and surgical procedures [64].

A dangerous complication of allogenic hematopoietic stem cell transplantation (allo-HSCT) is graft-versus-host disease (GvHD). One of the features of GvHD is peripheral and tissue eosinophilia. It seems that the presence of eosinophils in duodenal biopsies correlates with the disease severity but peripheral eosinophilia is associated with a better prognosis [65].

Primary (Addison's disease) or secondary adrenal insufficiency causes eosinophilia due to cortisol deficiency. Glucocorticoids have a pro-apoptotic effect regarding eosinophils, but they promote neutrophilia [66, 67].

The existence of nodules, eosinophilia, rheumatism, dermatitis and edema indicates the occurrence of an extraordinary NERDS syndrome. Swelling of hands or feet and osteoarticular pain result from nodules of tenosynovium. In the peripheral blood elevated values of IgE and eosinophil-derived proteins are noted [68]. Moreover, when eosinophilia and angioedema occur, two entities with different pathophysiology should be considered – the episodic angioedema with eosinophilia syndrome (Gleich's syndrome) and non-episodic angioedema with eosinophilia [69].

Rare causes of peripheral eosinophilia include Kimura's disease, which is a chronic, inflammatory illness. The most characteristic manifestation is benign nodules in the subcutaneous tissue and enlargement of the lymph nodes. The head and neck are the most common locations. It may also occur on the torso or limbs. Furthermore, lesions in the kidneys, orbit, outer ear and scrotum have also been described. Sometimes it is accompanied by allergic diseases or kidney disorders. Kimura's disease is often manifested by significant HE and an increase in IgE titers [70, 71].

Classification of primary hypereosinophilia

After exclusion of secondary causes of eosinophilia, the hematological diagnosis should be performed [9]. In hematological disorders eosinophilia can be caused by both intrinsic and extrinsic mechanisms. In stem cell and myelopoietic neoplasms, eosinophils are derived from the malignant clone, whereas in lymphoid neoplasms and reactive states, eosinophilia is usually triggered by eosinopoietic cytokines [1].

In the case of primary eosinophilia, the World Health Organization classification of myeloid neoplasms and

acute leukemia applies. In 2008 the classification of eosinophilic diseases was revised by the World Health Organization. A new major category of molecularly defined primary eosinophilias was created – “Myeloid and lymphoid neoplasms with eosinophilia and abnormalities of platelet derived growth factor receptor alpha (*PDGFRA*), platelet-derived growth factor receptor beta (*PDGFRB*), or fibroblast growth factor receptor 1 (*FGFR1*)” [9, 72]. Lymphocyte-variant hypereosinophilia and HES-I, which is a diagnosis of exclusion, were also established [72, 73]. Other subtypes, such as “chronic eosinophilic leukemia-not otherwise specified” (CEL-NOS), are within the major WHO category of myeloproliferative neoplasms (MPNs) [9, 72]. CEL, NOS is defined by the exclusion of other bone marrow neoplasms associated with eosinophilia, such as acute myelogenous leukemia, myelodysplastic syndrome (MDS), systemic mastocytosis (SM), the classic myeloproliferative neoplasms (MPN), and MDS/MPN overlap disorders. It is also necessary to establish the absence of the Philadelphia chromosome or abnormalities of *PDGFR*, *FGFR1* and *JAK2* (*PCM1-JAK2*, *ETV6-JAK2* or *BCR-JAK2* fusion genes) for diagnosis. CEL, NOS is characterized by an increase in blasts in the bone marrow or blood (but fewer than 20%) or by the evidence for clonality in the eosinophil lineage [9, 72, 73].

The current 2016 revision to the WHO classification maintained the division from 2008 [9, 74]. Another new temporary category has been added: “Myeloid/lymphoid neoplasms with *PCM1-JAK2*”. The fusion gene is formed on the basis of translocation t(8;9)(p22;p24.1). In the absence of this rearrangement of the *JAK2* gene, other variants are possible and meet the diagnostic criteria: t(9;12)(p24.1;p13.2) (*ETV6-JAK2* fusion gene) or t(9;22)(p24.1;q11.2) (*BCR-JAK2* fusion gene) [9]. Malignancies with rearrangements of *ETV6-JAK2* or *BCR-JAK2* genes are very infrequent and therefore not distinguished as individual entities. Most often, they were classified as the B-cell ALL variant. The new *JAK2* gene rearrangement subunit is provisional and requires further investigation [74, 75].

Importantly, the WHO classification has some crucial limitations. Current criteria based on the cytogenetic and molecular factors preclude logical division according to the histological type. Myeloid and lymphoid neoplasms may be classified as a common molecular category. Furthermore, detection of one driver mutation does not exclude the co-occurrence of others. The hierarchy of molecular changes is not determined. Additionally, co-existence of more than one malignancy is possible. For instance, the coincidence of a neoplasm with rearrangement of *FIP1L1/PDGFR*A and SM has been described [8]. Thus, recognizing one disease entity does not exclude others [76]. Nevertheless, the molecular division is very valuable because of its prognostic and predictive properties. The rearrangement of *PDGFRA/B* has a relatively good

prognosis. CEL-NOS and the *FGRFR1* or *JAK2* abnormalities are associated with poor prognosis. The existence of a specific fusion gene also determines the type of recommended treatment [8, 9, 77].

Moreover, it should be remembered that clonal HE may also be associated with other WHO-defined hematological neoplasms, i.e. SM, acute myeloid leukemia (AML), MDS, chronic myeloid leukemia (CML), other MPN and MDS/MPN overlap disorders [8, 9, 78].

Summary

Because of many underlying causes, the diagnosis of eosinophilia and eosinophil disorders is a great challenge not only for hematologists, but all physicians. Advancement in the diagnostics based on molecular criteria, targeted therapy and a greater understanding of the HE pathogenesis had an important impact on the survival of patients with HES. The analysis of the literature indicates a significant improvement in the prognosis. A literature review from the 1970s indicated that only 12% of patients with HES survived 3 years [9, 25]. In the 1980s, the 5-year survival rate increased to 80% [79]. Nowadays it is over 90%, with a significant improvement in long-term prognosis [9]. The continuous developments for better understanding of eosinophilia may improve diagnosis, treatment, and prognosis in this group of disorders.

Source of funding

This study was funded by a research grant of the Medical University of Lublin [DS176].

The authors declare no conflict of interest.

References

1. Valent P (2009): Pathogenesis, classification, and therapy of Eosinophilia and Eosinophil disorders. *Blood Rev* 23: 157-165.
2. Gleich GJ (2000): Mechanisms of Eosinophil-associated inflammation. *J Allergy Clin Immunol* 105: 651-663.
3. Valent P, Gleich GJ, Reiter A, et al. (2012): Pathogenesis and classification of eosinophil disorders: A review of recent developments in the field. *Expert Rev Hematol* 5: 157-176.
4. Falchi L, Verstovsek S (2015): Eosinophilia in hematologic disorders. *Immunol Allergy Clin North Am* 35: 439-452.
5. Gotlib J (2014): World Health Organization-defined Eosinophilic disorders: 2014 update on diagnosis, risk stratification, and management. *Am J Hematol* 89: 325-337.
6. Bridgen M, Graydon C (1997): Eosinophilia detected by automated blood cell counting in ambulatory North American outpatients. Incidence and clinical significance. *Arch Pathol Lab Med* 121: 963-967.
7. Tefferi A, Patnaik MM, Pardanani A (2006): Eosinophilia: Secondary, clonal and idiopathic. *Br J Haematol* 133: 468-492.
8. Valent P, Klion AD, Horny HP, et al. (2012): Contemporary consensus proposal on criteria and classification of Eosino-

- philic disorders and related syndromes. *J Allergy Clin Immunol* 130: 607-612.e9.
9. Gotlib J (2017): World Health Organization-defined Eosinophilic disorders: 2017 update on diagnosis, risk stratification, and management. *Am J Hematol* 92: 1243-1259.
 10. Brito-Babapulle F (2003): The Eosinophilias, including the idiopathic hypereosinophilic syndrome. *Br J Haematol* 121: 203-223.
 11. Gotlib J (2011): World Health Organization-defined Eosinophilic disorders: 2011 update on diagnosis, risk stratification, and management. *Am J Hematol* 86: 677-688.
 12. Kay AB (2016): Paul Ehrlich and the early history of granulocytes. *Microbiol Spectr* 4, doi: 10.1128/microbiolspec.MCHD-0032-2016.
 13. Fulkerson PC, Rothenberg ME (2018): Eosinophil development, disease involvement, and therapeutic suppression. *Adv Immunol* 138: 1-34.
 14. Mori Y, Iwasaki H, Kohno K, et al. (2009): Identification of the human eosinophil lineage-committed progenitor: Revision of phenotypic definition of the human common myeloid progenitor. *J Exp Med* 206: 183-193.
 15. Menzies-Gow A, Flood-Page P, Sehmi R, et al. (2003): Anti-IL-5 (Mepolizumab) therapy induces bone marrow eosinophil maturational arrest and decreases eosinophil progenitors in the bronchial mucosa of atopic asthmatics. *J Allergy Clin Immunol* 111: 714-719.
 16. Anderson EL, Kobayashi T, Iijima K, et al. (2016): IL-33 mediates reactive Eosinophilopoiesis in response to airborne allergen exposure. *Allergy* 71: 977-988.
 17. Simon D, Simon HU (2007): Eosinophilic disorders. *J Allergy Clin Immunol* 119: 1291-1300.
 18. Woolnough K, Wardlaw AJ (2015): Eosinophilia in pulmonary disorders. *Immunol Allergy Clin North Am* 35: 477-492.
 19. Uribe Echevarría L, Leimgruber C, García González J, et al. (2017): Evidence of eosinophil extracellular trap cell death in COPD: Does it represent the trigger that switches on the disease? *Int J Chron Obstruct Pulmon Dis* 12: 885-896.
 20. Curtis C, Ogbogu P (2016): Hypereosinophilic syndrome. *Clin Rev Allergy Immunol* 50: 240-251.
 21. Zimmermann N, Wikenheiser-Brokamp KA (2018): Hypereosinophilic syndrome in the differential diagnosis of pulmonary infiltrates with eosinophilia. *Ann Allergy Asthma Immunol* 121: 179-185.
 22. Cheung AC, Hachem CY, Lai J (2016): Idiopathic hypereosinophilic syndrome presenting with hepatitis and achalasia. *Clin J Gastroenterol* 9: 238-242.
 23. Yamada Y, Rothenberg ME, Cancelas JA (2006): Current concepts on the pathogenesis of the hypereosinophilic syndrome/chronic eosinophilic leukemia. *Transl Oncogenomics* 1: 53-63.
 24. Kahn JE, Groh M, Lefčvre G (2017): (A Critical Appraisal of) Classification of Hypereosinophilic Disorders. *Front Med (Lausanne)* 4: 216.
 25. Chusid MJ, Dale DC, West BC, Wolff SM (1975): The hypereosinophilic syndrome: Analysis of fourteen cases with review of the literature. *Medicine (Baltimore)* 54: 1-27.
 26. Klion AD, Law MA, Riemenschneider W, et al. (2004): Familial Eosinophilia: A benign disorder? *Blood* 103: 4050-4055.
 27. Khoury, P.; Bochner, B.S. Consultation for Elevated Blood Eosinophils: Clinical Presentations, High Value Diagnostic Tests, and Treatment Options. *J Allergy Clin Immunol Pract* 2018, 6, 1446–1453, doi:10.1016/j.jaip.2018.04.030.
 28. O'Connell EM, Nutman TB (2015): Eosinophilia in infectious diseases. *Immunol Allergy Clin North Am* 35: 493-522.
 29. Gajadhar AA, Pozio E, Gamble HR, et al. (2009): *Trichinella* diagnostics and control: Mandatory and best practices for ensuring food safety. *Vet Parasitol* 159: 197-205.
 30. Sharma RK, Raghavendra N, Mohanty S, et al. (2014): Clinical & biochemical profile of trichinellosis outbreak in North India. *Indian J Med Res* 140: 414-419.
 31. Hall RL, Lindsay A, Hammond C, et al. (2012): Outbreak of human Trichinellosis in Northern California caused by *Trichinella Murrelli*. *Am J Trop Med Hyg* 87: 297-302.
 32. Webb CM, Cabada MM (2018): Recent developments in the epidemiology, diagnosis, and treatment of fasciola infection. *Curr Opin Infect Dis* 31: 409-414.
 33. de Jesus AR, Silva A, Santana LB, et al. (2002): Clinical and immunologic evaluation of 31 patients with acute schistosomiasis mansoni. *J Infect Dis* 185: 98-105.
 34. Khan A, Zahoor S, Ahmed H, et al. (2018): A retrospective analysis on the cystic echinococcosis cases occurred in Northeastern Punjab province, Pakistan. *Korean J Parasitol* 56: 385-390.
 35. Fahim F, Al Salamah SM (2007): Cystic Echinococcosis in Central Saudi Arabia: A 5-year experience. *Turk J Gastroenterol* 18: 22-27.
 36. Lv H, Jiang Y, Liu G, et al. (2015): Surgical treatment of multiple hydatid cysts in the liver of a pediatric patient. *Am J Trop Med Hyg* 92: 595-598.
 37. Schulte C, Krebs B, Jelinek T, et al. (2002): Diagnostic significance of blood eosinophilia in returning travelers. *Clin Infect Dis* 34: 407-411.
 38. Allen J, Wert M (2018): Eosinophilic pneumonias. *J Allergy Clin Immunol Pract* 6: 1455-1461.
 39. Duray PH (1989): Clinical pathologic correlations of Lyme disease. *Rev Infect Dis* 11 Suppl 6: S1487-1493.
 40. Buda P, Zawadka K, Wadowska-Kłopotek W, et al. (2015): Cerebrospinal fluid eosinophilia in a child with neuroborreliosis. *Wiad Lek* 68: 92-94.
 41. Granter SR, Barnhill RL, Duray PH (1996): Borreliac fasciitis: Diffuse fasciitis and peripheral eosinophilia associated with borrelia infection. *Am J Dermatopathol* 18: 465-473.
 42. Garg G, Gogia A, Kakar A, Miglani P (2017): Persistent marked peripheral eosinophilia due to tuberculosis: A case report. *Iran J Med Sci* 42: 102-105.
 43. Chou A, Serpa JA (2015): Eosinophilia in patients infected with human immunodeficiency virus. *Curr HIV/AIDS Rep* 12: 313-316.
 44. Newby C, Agbetile J, Hargadon B, et al. (2014): Lung function decline and variable airway inflammatory pattern: Longitudinal analysis of severe asthma. *J Allergy Clin Immunol* 134: 287-294.
 45. Loutsios C, Farahi N, Porter L, et al. (2014): Biomarkers of eosinophilic inflammation in asthma. *Expert Rev Respir Med* 8: 143-150.
 46. Pashley CH (2014): Fungal culture and sensitisation in asthma, cystic fibrosis and chronic obstructive pulmonary disorder: What does it tell us? *Mycopathologia* 178: 457-463.
 47. Ho MHK, Wong WHS, Chang C (2014): Clinical spectrum of food allergies: A comprehensive review. *Clin Rev Allergy Immunol* 46: 225-240.
 48. Lyons JJ, Milner JD, Stone KD (2015): Atopic dermatitis in children: Clinical features, pathophysiology, and treatment. *Immunol Allergy Clin North Am* 35: 161-183.
 49. Cuestas D, Forero Y, Galvis I, et al. (2018): Drug reaction with eosinophilia and systemic symptoms (DRESS) and mul-

- tiple organ dysfunction syndrome (MODS): One more reason for a new effective treatment against leishmaniasis. *Int J Dermatol* 57: 1304-1313.
50. Bocquet H, Bagot M, Roujeau JC (1996): Drug-induced pseudolymphoma and drug hypersensitivity syndrome (drug rash with eosinophilia and systemic symptoms: DRESS). *Semin Cutan Med Surg* 15: 250-257.
 51. Descamps V, Ranger-Rogez S (2014): DRESS syndrome. *Joint Bone Spine* 81: 15-21.
 52. Pichler WJ, Adam J, Watkins S, et al. (2015): Drug hypersensitivity: How drugs stimulate T cells via pharmacological interaction with immune receptors. *Int Arch Allergy Immunol* 168: 13-24.
 53. Roujeau JC, Dupin N (2017): Virus reactivation in drug reaction with eosinophilia and systemic symptoms (Dress) results from a strong drug-specific immune response. *J Allergy Clin Immunol Pract* 5: 811-812.
 54. Tamaki H, Chatterjee S, Langford CA (2015): Eosinophilia in rheumatologic/vascular disorders. *Immunol Allergy Clin North Am* 35: 453-476.
 55. Jakiela B, Szczeklik W, Plutecka H, et al. (2012): Increased production of IL-5 and dominant Th2-type response in airways of Churg-Strauss syndrome patients. *Rheumatology (Oxford)* 51: 1887-1893.
 56. Hilhorst M, Maria AT, Kavian N, et al. (2018): Impact of MPO-ANCA-mediated oxidative imbalance on renal vasculitis. *Am J Physiol Renal Physiol* 315: F1769-F1776.
 57. Khoury P, Zagallo P, Talar-Williams C, et al. (2012): Serum biomarkers are similar in Churg-Strauss syndrome and hyper-eosinophilic syndrome. *Allergy* 67: 1149-1156.
 58. Legatowicz-Koprowska M (2018): IgG4-related disease: Why is it so important? *Cent Eur J Immunol* 43: 204-208.
 59. Allen JA, Peterson A, Sufit R, et al. (2011): Post-epidemic eosinophilia-myalgia syndrome associated with L-tryptophan. *Arthritis Rheum* 63: 3633-3639.
 60. Selva-O'Callaghan A, Trallero-Araguás E, Grau JM (2014): Eosinophilic myositis: An updated review. *Autoimmun Rev* 13: 375-378.
 61. Brugnani D, Airó P, Rossi G, et al. (1996): A case of hyper-eosinophilic syndrome is associated with the expansion of a CD3-CD4+ T-cell population able to secrete large amounts of interleukin-5. *Blood* 87: 1416-1422.
 62. Rigoni A, Colombo MP, Pucillo C (2018): Mast cells, basophils and eosinophils: From allergy to cancer. *Semin Immunol* 35: 29-34.
 63. Carretero R, Sektioglu IM, Garbi N, et al. (2015): Eosinophils orchestrate cancer rejection by normalizing tumor vessels and enhancing infiltration of CD8(+) T cells. *Nat Immunol* 16: 609-617.
 64. Click B, Anderson AM, Koutroubakis IE, et al. (2017): Peripheral eosinophilia in patients with inflammatory bowel disease defines an aggressive disease phenotype. *Am J Gastroenterol* 112: 1849-1858.
 65. Imahashi N, Miyamura K, Seto A, et al. (2010): Eosinophilia predicts better overall survival after acute graft-versus-host-disease. *Bone Marrow Transplant* 45: 371-377.
 66. Charmandari E, Nicolaidis NC, Chrousos GP (2014): Adrenal insufficiency. *Lancet* 383: 2152-2167.
 67. Saffar AS, Ashdown H, Gounni AS (2011): The molecular mechanisms of glucocorticoids-mediated neutrophil survival. *Curr Drug Targets* 12: 556-562.
 68. Singh AD, Suri TM, Jagdish RK, Kumar U (2018): Unravelling the NERDS syndrome. *BMJ Case Rep* 2018: ber2017223506, ber-2017-223506.
 69. Banerji A, Weller PF, Sheikh J (2006): Cytokine-associated angioedema syndromes including episodic angioedema with eosinophilia (Gleich's syndrome). *Immunol Allergy Clin North Am* 26: 769-781.
 70. Zhu S, Wei P, Chen J, et al. (2015): Diagnosis and treatment of a patient with Kimura's disease associated with nephrotic syndrome and lymphadenopathy of the epitrochlear nodes. *BMC Nephrol* 16: 10.
 71. Xie DP, Xu YF, Li MQ (2018): Kimura's disease presenting as scrotal mass: A difficult diagnosis. *Urol J* 15: 295-296.
 72. Pardanani A, Tefferi A (2008): Primary eosinophilic disorders: A concise review. *Curr Hematol Malig Rep* 3: 37-43.
 73. Helbig G, Soja A, Bartkowska-Chrobok A, Kyrz-Krzemień S (2012): Chronic eosinophilic leukemia-not otherwise specified has a poor prognosis with unresponsiveness to conventional treatment and high risk of acute transformation. *Am J Hematol* 87: 643-645.
 74. Arber DA, Orazi A, Hasserjian R, et al. (2016): The 2016 revision to the World Health Organization classification of myeloid neoplasms and acute leukemia. *Blood* 127: 2391-2405.
 75. Bain BJ, Ahmad S (2014): Should myeloid and lymphoid neoplasms with PCM1-JAK2 and other rearrangements of JAK2 be recognized as specific entities? *Br J Haematol* 166: 809-817.
 76. Wang L, Pan Q, Fu J, et al. (2008): FIP1L1-PDGFRalpha alone or with other genetic abnormalities reveals disease progression in chronic eosinophilic leukemia but good response to imatinib. *Chin Med J (Engl)* 121: 867-873.
 77. Gotlib J (2015): Tyrosine kinase inhibitors and therapeutic antibodies in advanced eosinophilic disorders and systemic mastocytosis. *Curr Hematol Malig Rep* 10: 351-361.
 78. Tefferi A, Gotlib J, Pardanani A (2010): Hyper-eosinophilic syndrome and clonal eosinophilia: Point-of-care diagnostic algorithm and treatment update. *Mayo Clin Proc* 85: 158-164.
 79. Lefebvre C, Bletry O, Degoulet P, et al. (1989): Prognostic factors of hyper-eosinophilic syndrome. Study of 40 cases. *Ann Med Interne (Paris)* 140: 253-257.