

Hybrid treatment of type 2 right sided aortic arch and Kommerell's diverticulum in an octogenarian

Serkan Burc Deser

Department of Cardiovascular Surgery, Institute of Cardiology, Istanbul University-Cerrahpasa, Istanbul, Turkey

Kardiocirurgia i Torakochirurgia Polska 2023; 20 (1): 60-61



Right-sided aortic arch accompanying aberrant left subclavian artery is mostly asymptomatic and incidentally detected. Guidelines or surgical indications for Kommerell's diverticulum have not been established because of the rareness of the anomaly. Ota *et al.* [1] recommend treating patients with the diameter of Kommerell's diverticulum more than 50 mm in patients who had symptoms associated with Kommerell's diverticulum. Czerny *et al.* [2] stated that aberrant subclavian arteries ≥ 3 cm in diameter and Kommerell's diverticula with a diameter ≥ 5.5 and in addition symptomatic patients should be treated. Symptoms including dysphagia, respiratory failure, or chest pain can be present in 5% of patients. Treatments options include open surgery via sternotomy or thoracotomy under deep hypothermic circulatory and endovascular and hybrid surgery [3]. An 84-year-old man who presented with pneumonia due to compression of the trachea was admit-

ted to our hospital. Computed tomography revealed right-sided aortic arch and the left subclavian artery arose from the descending aorta in a Kommerell's diverticulum. The right-sided descending aorta had a maximum diameter of 45 mm and the diverticulum had a 25 mm diameter. He was intubated in the emergency service due to severe dyspnea and appropriate antibiotic therapy was administered. After informed consent had been taken from the patient's family, a tracheostomy was performed 2 weeks after intubation. Due to compression symptoms of Kommerell's diverticulum, the first stage was performed via a subclavian artery to carotid artery transposition and the second stage was performed via thoracic endovascular repair (TEVAR) with $40 \times 40 \times 150$ mm Valiant Captivia (Medtronic, Santa Rosa, Calif) endograft. Postoperative computed tomography showed complete exclusion of the diverticulum and no endoleaks (Figures 1 A–F). He was removed from the venti-

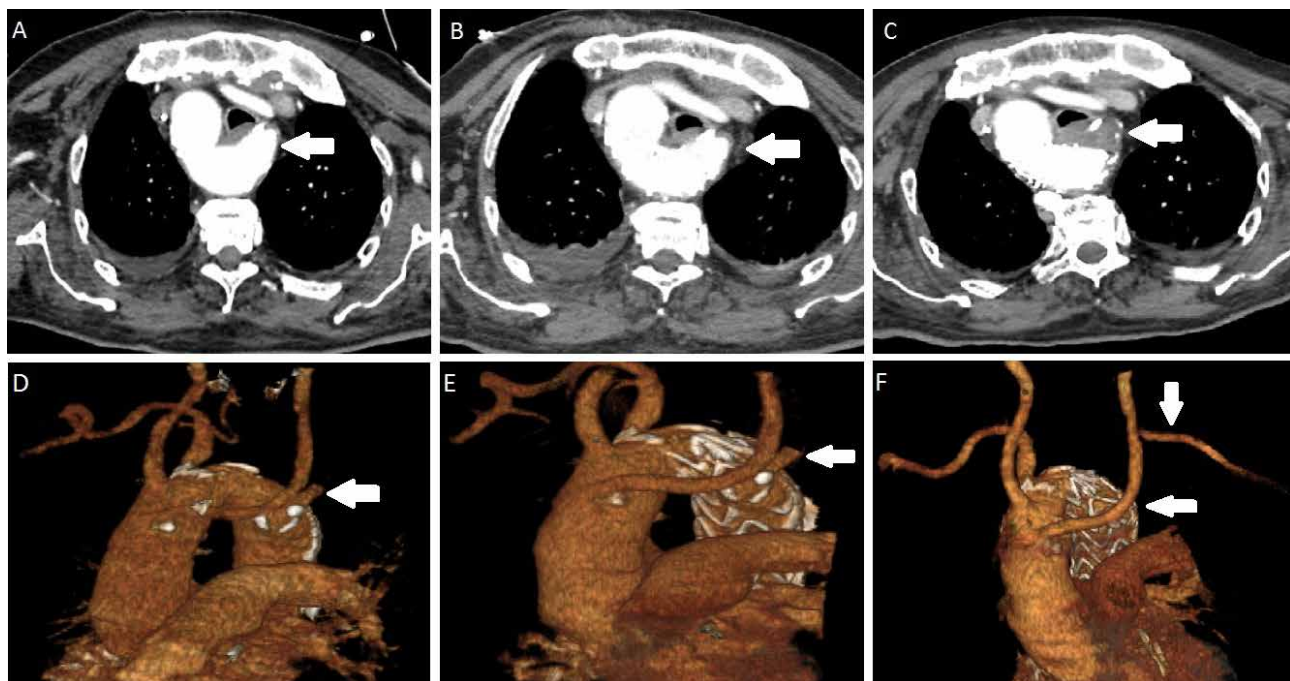


Figure 1. Preoperative (A, D), after TEVAR (B, E), after left subclavian artery to carotid artery transposition computed tomography scans (C, F)

Address for correspondence: Dr Serkan Burc Deser, Department of Cardiovascular Surgery, Institute of Cardiology, Istanbul University-Cerrahpasa, Istanbul, Turkey, phone: +902124592000, e-mail: sbd983@yahoo.com

Received: 4.03.2022, **accepted:** 6.02.2023.

lator 2 weeks later and discharged at 1 month postoperatively. Six months later he was doing well without dyspnea and endoleak. Here, we report a case of successful hybrid treatment and resolution of a Kommerell's diverticulum.

Disclosure

The author reports no conflict of interest.

References

1. Ota T, Okada K, Takanashi S, Yamamoto S, Okita Y. Surgical treatment for Kommerell's diverticulum. *J Thorac Cardiovasc Surg* 2006; 131: 574-578.
2. Czerny M, Schmidl J, Adler S, van den Berg JC, Bertoglio L, Carrel T, Chiesa R, Clough RE, Eberle B, Eitz C, Grabenwöger M, Haulon S, Jakob H, Kari FA, Messtres CA, Pacini D, Resch T, Rylski B, Schoenhoff F, Shrestha M, von Tengg-Koblick H, Tsagakis K, Wyss TR; EACTS/ESVS scientific document group. Current options and recommendations for the treatment of thoracic aortic pathologies involving the aortic arch: an expert consensus document of the European Association for Cardio-Thoracic surgery (EACTS) and the European Society for Vascular Surgery (ESVS). *Eur J Cardiothorac Surg* 2019; 55: 133-162.
3. Kazuno K, Murata S. Endovascular repair for Kommerell's diverticulum and right-sided aortic arch. *Ann Vasc Dis* 2017; 10: 48-50.